



JACOB SHEEP BREEDERS ASSOCIATION

INSPECTION COMMITTEE FACT SHEET

SPLIT UPPER EYELID DEFORMITY (SUED)

October 2019

LANGUAGE FROM THE JSBA BREED STANDARD:

- Desirable Traits: **Clear, bright eyes, no evidence of split upper eyelid deformity**
- Acceptable but Less Desirable Traits: **Grade 2 or 3 split upper eyelid deformity causing no injury to the eye which would require surgical intervention**
- Unacceptable/Disqualifying Traits: **Grade 3 split upper eyelid deformity or more, causing discomfort or injury to eye**

DEFINITION FROM THE JSBA GUIDEBOOK:

Split eyelid deformity: Fault found in some polycerate sheep breeds where the eyelash edge does not form a continuous, unbroken line (normal), but instead has a notch (mildest form) or an inverted V shaped split (most severe form). In the worst cases, the eyelid with lashes may be curled into the eye causing abrasions and ulceration leading to blindness. This trait is genetically carried by both four-horned and two-horned sheep.¹ The two-horned ram may suppress the expression of this trait, but will not remove it from the genetic inheritance of its offspring. Each eyelid should be scored separately. A score of 1 is normal with 4 describing a severe split. All Jacobs should be carefully examined and the correct score for each eyelid recorded on registration forms.

GRADING OF SUED FROM THE JSBA REGISTRATION APPLICATION:

Type 1: Normal

Type 2: Slight break/notch

Type 3: Split eyelid, often tufted

Type 4: Split, often cloudy/opaque

¹ This statement is quoted from the JSBA Guidebook, but Inspection Committee members note that given current uncertainty regarding the method of inheritance, it may or may not be totally correct.

DISCUSSION AND ILLUSTRATIONS

The following photos are intended to illustrate the appearance of different scores or types of SUED. However, these numbered types in fact illustrate a full range of the SUED condition, with no absolute line between – for example – a Type 3 and a Type 4. For this reason, a closeup photo of the impacted eye is requested with registration applications that indicate the presence of SUED. In addition, it may be difficult to show irritation to the eye in a photo, but the breeder can make note of the eye condition on the application.

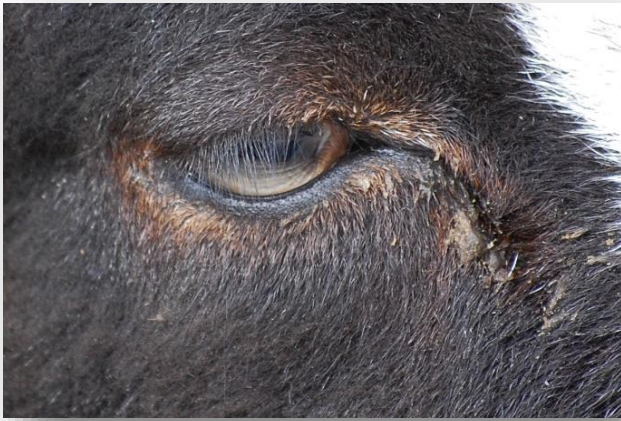

Photo 1: Type 1 or Normal eye. No break in line of eyelashes, tuft on eyelid, or notch in eyelid.

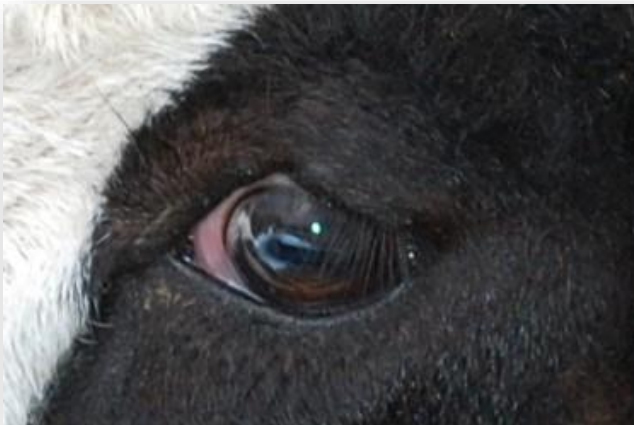

Photo 2: Type 2 – a very slight notch or break in the upper eyelid. A small break may not be apparent unless the eyelid is gently stretched.

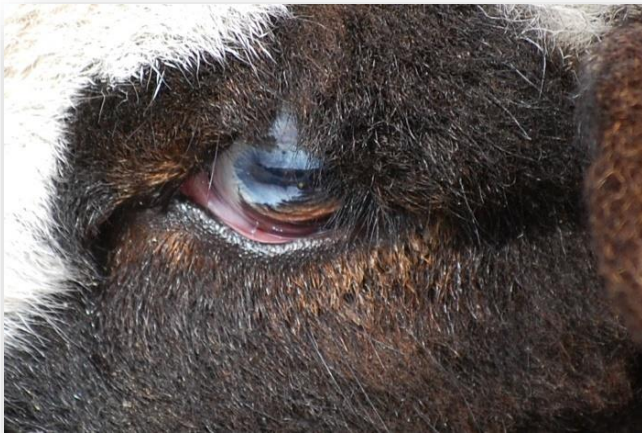

Photo 3: Type 3 – a definite split in the eyelid. Some tufting or longer hair next to the split. No irritation of the eye visible.

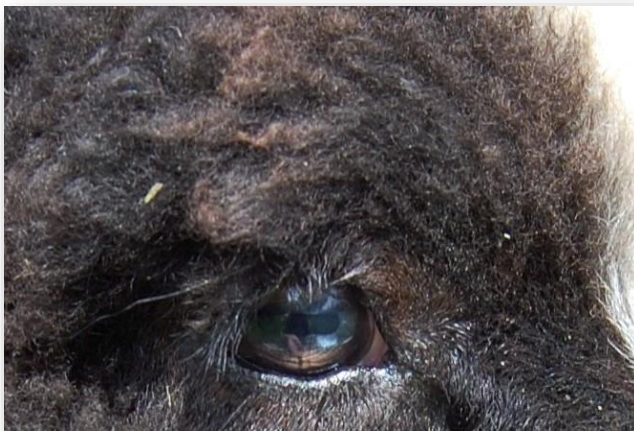

Photo 4. A Type 3 split – note the vertical row of longer wool and long hairs above the split. The split itself would be more obvious if the eyelid were stretched - it may possibly be a Type 4.



Photo 5. Type 3 - Definite split, without folding under of eyelid. Although difficult to see in this photo, there is a cloudiness (dull patch) apparent at the point of the split that indicates eye irritation.

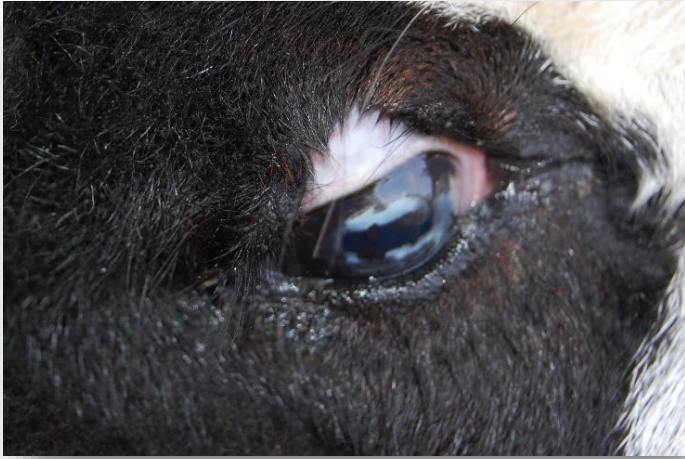

Photo 6. Type 4. Definite split, edge of eyelid folded under, irritation in the eye (although not readily visible in this photo).

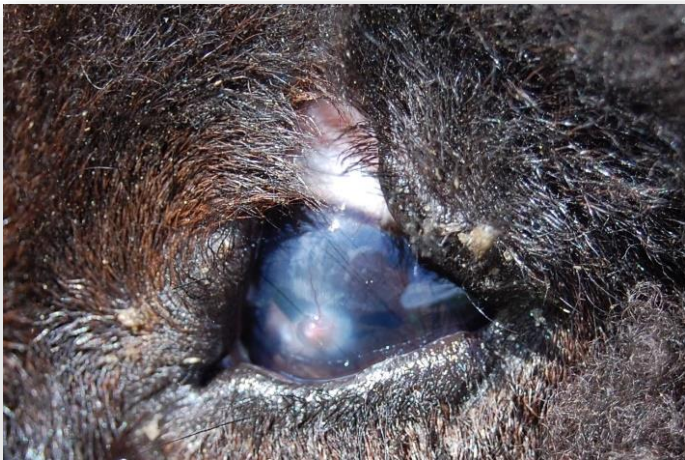

Photo 7. Type 4. Definite split, turning under of eyelid. Irritation of the eye is readily visible – note ulcer on the eye.

Why is SUE important?

There are two important factors to keep in mind regarding SUE in Jacobs.

- 1. The more obvious and serious types of this deformity can result in irritation and injury to the eye.** A more severe split may result in the edge of the eyelid being rolled back into the eye, resulting in irritation of the eye by the eyelashes – a condition termed “entropion.” Even where entropion does not occur, the cornea of the eye can be irritated because the eyelid does not totally protect it. The cornea may become cloudy or opaque, and cysts or ulcers may result (see photo #7 above).

The JSBA Standard prohibits registration of animals with SUE that may result in injury to the eye, including all Type 3’s and Type 4’s that show irritation.

- 2. On the other hand, SUED is associated with the presence of 4 or more horns, and excessive culling of individuals with SUED can reduce the number and thus the diversity of 4-horned sheep.** SUED is found in several other 4-horned breeds, including Navajo-Churro, Icelandic, Hebridean, Manx Loaghtan, and Damara. It has also been observed in a type of multi-horned goat found in Spain. Breeders have attempted to reduce the incidence of SUED in many of these breeds by culling affected individuals; this has in some instances greatly reduced the percentage of multi-horned (or polycerate) sheep. For example, Hebridean sheep – a British heritage breed – were reportedly predominantly 4-horned in the past. However, by 2011, only 7.4% of the breeding population was multi-horned.

The JSBA Breed Standard balances these two factors by prohibiting registration of Jacobs with SUED that has or is likely to result in eye injury but allowing registration of less severely affected individuals. However, the decisions of individual breeders will also impact the breed. Some breeders may choose to cull animals showing any sign of SUED, while others will register and breed animals with very slight or more obvious but not injurious SUED.

Moreover, breeders might interpret the “types” of SUED differently, given that the condition is present in a range or continuum; there are no hard lines among the categories other than presence or absence of SUED. Finally, even consideration of SUED by registration inspectors most often depends primarily on information reported by the owner on the application form, given that the eyes do not show clear detail in most photos.

The following information is thus intended to help guide breeders in their decisions about animals with SUED. There is currently no “right” or “wrong” approach, other than compliance with the Standard if registering with JSBA. In fact, additional research is needed to clarify some issues.

Heritability

It is well established that SUED is associated in some manner to the genetic multi-horned sheep. However, unlike the inheritance of 2 horns versus 4 horns, little is known about the mechanism of inheritance of SUED.

One of the most detailed studies of SUED was conducted on Hebridean sheep in 2011 – see references for a link to the published paper. This study was based on examination of 473 pure-bred Hebridean sheep, including 17 two-horned sheep. Of these animals, 9.7% of adults and 17.6% of lambs had SUED (as defined by the JSBA standard) in one or both eyes². By statistical analysis of all animals and information regarding their known parents it was determined that:

- There was no statistically significant difference in the percentage of SUED between rams and ewes.

² SUED was observed in only one “2-horned” lamb; we assume that lamb could well have been a fused 4-horned animal.

- The presence of SUED in the sire and/or the dam *did not* predict whether their offspring would have SUED (although there appears to be some genetic connection).
- SUED appeared to be less common in 5-horned animals compared with 4-horned animals, although the sample number showing this was very small.
- SUED *did not* appear to be associated with the presence of scurs.
- SUED *did* appear to be associated with forward-facing horns (as opposed to vertical or rear-facing horns). However, the authors of the paper noted that this finding could have been influenced by heavy culling of sheep with forward horns regardless of SUED.
- There *did not* appear to be a different level of SUED among the flocks that were included in the study, even though the culling practices in different flocks varied. This implies that culling does not greatly influence the occurrence of SUED.

In comparing this study to one carried out in 1981 that reported that 18.6% of Hebridean sheep were positive for SUED in at least one eye, the researchers concluded that there was no significant change in expression of SUED over a 30-year period of breeding during which SUED was a consideration. It should be noted that the Hebridean breed association allows registration of ewes with a less serious type of SUED.

While this study focused on a different breed, it is likely that inheritance of SUED is similar in the various polycerate breeds. While the mechanism of SUED inheritance has not been determined, it seems clear that culling of animals that exhibit SUED may not significantly reduce the occurrence of SUED. However, culling of all affected sheep *will* reduce the number and thus the genetic diversity of multi-horned animals.

Impact on eye health

There is little doubt that Types 3 and 4 SUED can result in irritation of the eye. Research on the Hebridean sheep discussed above also included testing all sheep with Rose Bengal – a harmless dye that turns red when the surface of the cornea is damaged. This test is used to detect minor eye irritation in both humans and animals. A high percentage of animals having a definite split in their upper eyelid (e.g. Types 3 and 4) tested positive for irritation. On the other hand, the breeders involved in the study did not report any other negative impacts on the welfare of the sheep. The authors of the study recommend more detailed analysis of factors, such as weight gain.

Visible irritation in the eyes of Jacobs with Types 3 or 4 SUED is fairly common – even in very young animals – see photos 5 and 7 above. One could anticipate that irritation and damage to the eye may increase over the lifespan of the animal.

Can SUED be corrected surgically?

At least two veterinarians who are JSBA members have surgically repaired a split in a sheep's upper eyelid. The following information regarding the procedure was provided by Lillian Royal, of Wiggle Hill Jacobs, and may be shared with your veterinarian.

We would not expect surgical repair to be routine, since animals with a severe condition cannot be registered and should not be bred. And of course, the surgical repair will not correct the genetic issue. However, there may be situations where this knowledge is useful, e.g. where an animal (such as a bred ewe) with a moderate form of SUED that passes inspection develops more severe eye-irritation as she ages, or where the sheep is kept as a pet. Dr. Royal notes that she only does the repair if a lamb seems uncomfortable with their SUED: squinting, corneal ulceration, etc. She tries to place these lambs in non-breeding homes as fiber animals or pets.

The following series of photos shows the procedure that Dr. Royal uses.

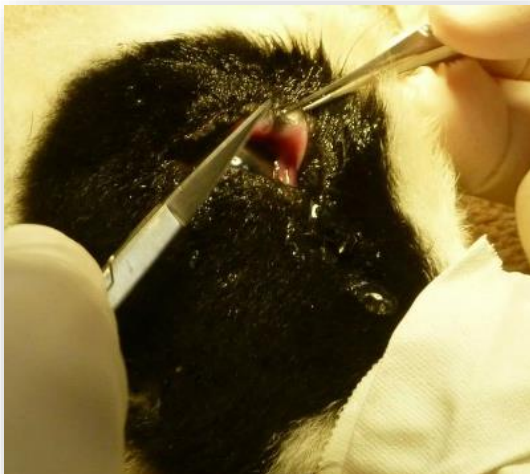

Photo 1: This is a photo of the underside of the lamb's upper eyelid, you can see the tuft of hair growing underneath and causing irritation to the surface of the cornea.

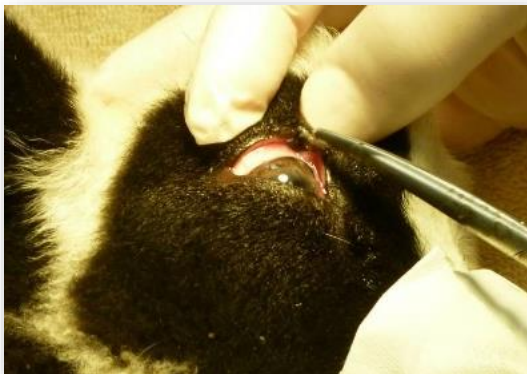

Photo 2: This photo shows the outer edge of the eyelid before repair.

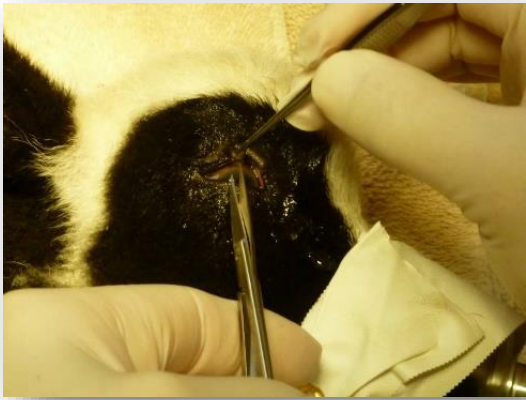

Photo 3: The surgical procedure basically involves excising the entire defect with fine, sharp scissors in a V or U shape. This is the beginning of the excision.

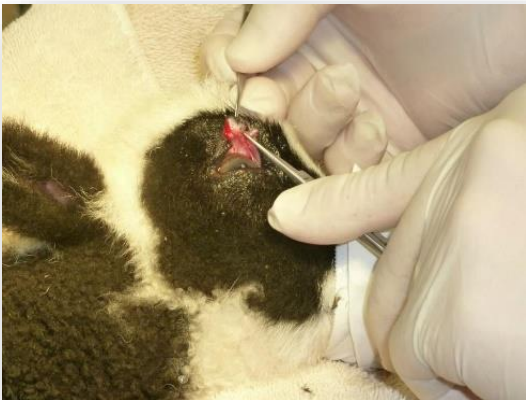

Photo 4: Continuing the incision on the other side of the defect.

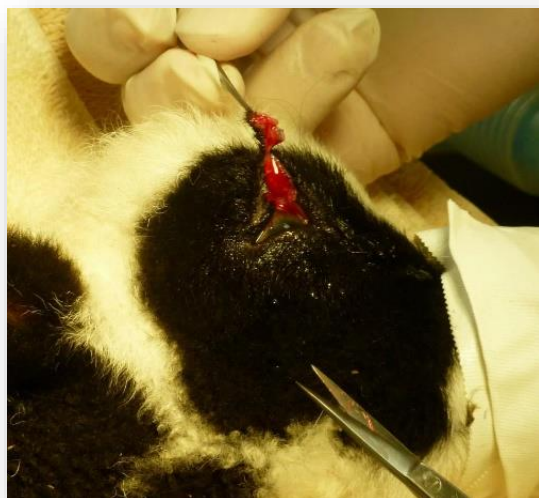


Photo 5: The defect is almost completely excised here.

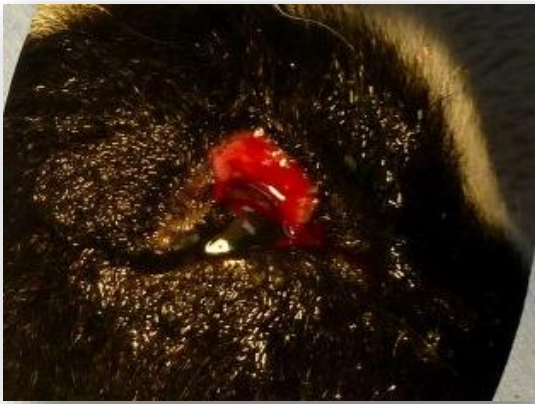

Photo 6: The defect is completely removed. This photo shows the U-shaped area that is left before suturing.

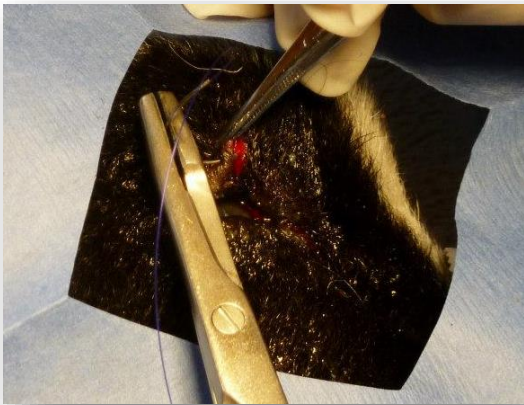


Photo 7: Closure is done with fine suture in a double layer.

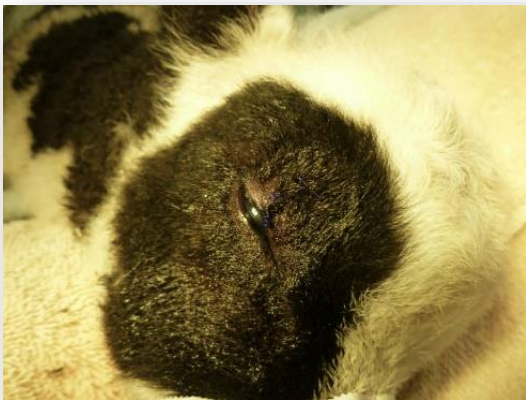


Photo 8: All done!

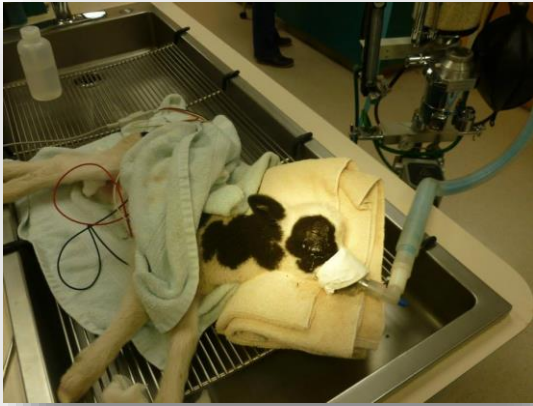

Photo 9: This is what the lamb looks like hooked up to the anesthesia and monitors.

Ongoing studies of SUED

The Inspection Committee located additional published papers that discussed SUED in Jacobs. Gary Anderson summarized one of these in his article *Modern Genetics Tackles the Four-Horned Gene in Jacob Sheep* in the JSBA Newsletter in 2018, cited below. This research was inconclusive regarding the genetic relationship of SUED and multiple horns in Jacobs.

Another published paper located by the JSBA Inspection Committee attempted to evaluate a number of genetic factors in Jacobs but, unfortunately, we were advised by research professionals that the selection of data and statistical methods used in writing that article resulted in questionable conclusions. It is not cited here. However, the inspection committee will continue to follow work on SUED and update this fact sheet as appropriate.

References

Anderson Gary. *Modern Genetics Tackles the Four-Horned Gene in Jacob Sheep*. JSBA Newsletter Spring, 2018. Vol. 30, Issue 2, pages 6-7.

Gascoigne, Emily & Williams, David & K Reyher, Kristen. (2017). *Survey of prevalence and investigation of predictors and staining patterns of the split upper eyelid defect in Hebridean sheep*. Veterinary Record. 181. vetrec-2016. 10.1136/vr.104082.

Royal, Lillian, DVM. Personal contact. Wilkes Veterinary Hospital, North Wilkesboro, NC 336-667-1109